

## ORIGINAL RESEARCH

**Risk Stratification of Severely Dysplastic Nevi by Non-Invasively Obtained Gene Expression and Mutation Analyses**

Stephanie R. Jackson, MD, PhD<sup>1</sup>; Burkhard Jansen, MD<sup>2</sup>; Zuxu Yao, PhD<sup>2</sup>; and Laura K. Ferris, MD, PhD<sup>1</sup>

<sup>1</sup>Department of Dermatology, University of Pittsburgh, Pittsburgh, PA

<sup>2</sup>DermTech, Inc., La Jolla, CA

## ABSTRACT

**Importance:** Strategies to non-invasively detect cutaneous melanoma generally focus on differentiating melanoma from non-melanoma lesions. However, given the variabilities in practice and lack of guidelines, it is important for clinicians to understand how such strategies and technologies perform on borderline lesions of uncertain clinical behavior.

**Objective:** To evaluate LINC and PRAME gene expression and the presence of somatic mutations in BRAF, NRAS, and/or TERT in severely dysplastic nevi (SDN) and to assess, how combining gene expression and mutation analyses may impact test performance.

**Methods:** One hundred three eligible skin lesions clinically suspicious for melanoma were non-invasively sampled via adhesive patches to enable genomic analyses. These same lesions were also immediately afterwards surgically biopsied to enable comparisons of genomic analyses with histopathologic diagnoses rendered by a panel of three dermatopathologists. Twenty-three of these lesions analyzed were deemed borderline lesions of SDN histology by at least one dermatopathologist. RNA-based gene expression positivity by Pigmented Lesion Assay (PLA) analysis was defined by detectable levels of LINC and/or PRAME. DNA-based mutation positivity was defined as detection of somatic mutations in BRAF (non-V600E), NRAS, and/or the TERT promoter.

**Results:** Adding TERT mutation analyses to PLA gene expression increases the test's sensitivity to rule out melanoma from 93% to 97% in this study. In addition, 61% of PLA positive lesions that were not diagnosed as melanoma were found to have severe histologic atypia. PLA-positive lesions histopathologically diagnosed as melanomas harbored TERT mutations in 70% of cases while both SDN and non-melanoma lesions including nevi without severe histologic atypia harbored TERT mutations in 4% of cases. BRAF non-V600E and NRAS mutations were only found in the melanoma group and adding these mutations did not further enhance the test's sensitivity.

**Conclusions and Relevance:** PLA positivity increases with histologic atypia of pigmented skin lesions. Combining TERT mutation analyses with melanoma-associated gene expression provides additional genetic information to further non-invasively risk-stratify pigmented lesions. These findings furthermore support that pigmented lesions exist on a spectrum of genomic atypia that may prove useful in identifying borderline lesions beyond their morphological appearance.

## INTRODUCTION

Pigmented lesions sharing overlapping histologic features with conventional nevi and melanoma have been termed ‘dysplastic nevi’ (DN).<sup>1</sup> The degree to which these lesions resemble the architectural disorder and cytologic atypia found in melanoma is used to stratify them as mildly, moderately, or severely dysplastic. Overlapping histologic features and low intra- and inter-observer agreement in the diagnosis of early melanoma raise concern that morphologic features of biopsied severely dysplastic nevi (SDN) may represent changes that could be diagnosed as early melanoma by some pathologists irrespective of the underlying tumor biology these changes may or may not be linked to. This challenge has resulted in the standard practice of ensuring complete removal of lesions characterized as SDN.<sup>2-4</sup> While some melanomas do arise within dysplastic nevi, the majority do not, and some propose that routine re-excision of all SDN may not be necessary.<sup>5,6</sup> Improved ability to stratify the malignant potential in these borderline lesions could spare patients unnecessary procedures.

Mounting evidence suggests that the morphologic features of DN correlate with mutational or gene expression changes that may represent the earliest indicators of progression from nevus to melanoma.<sup>1</sup> Advancements in molecular testing may aid in stratifying biologic risk and help to diagnose potentially aggressive lesions earlier. The pigmented lesion assay (PLA, DermTech, La Jolla, CA) is a non-invasive molecular test capable of helping to diagnose melanoma early with high sensitivity, specificity, and a high negative predictive value.<sup>7,8</sup> This test uses adhesive patches for sample collection and evaluates expression of RNA transcripts encoding LINC (long

intergenic non-coding RNA 518) and PRAME (preferentially expressed antigen in melanoma), both known to be overexpressed in melanoma.<sup>7,9</sup> Additionally, high-risk DNA driver mutations (BRAF non-V600E, NRAS, TERT) commonly found in early-stage melanoma can also be assessed using the same adhesive patch – based skin sample collection platform.<sup>2,10</sup> Combining these DNA and RNA risk factors enhances the ability to non-invasively detect melanoma.<sup>10</sup> The objective of our current study was to evaluate the expression of LINC, PRAME, and select melanoma driver mutations in clinically-challenging borderline lesions such as SDN and compare findings to lesions at both ends of the pigmented lesion spectrum where less controversy about management exists.

## METHODS

Data on 103 pigmented skin lesions clinically suspicious for melanoma (60 male and 43 female patients, median age 48 years) was collected under a protocol approved by the Western-Copernicus Group (Santee, CA) independent review board as previously described.<sup>10</sup> Epidermal lesional skin samples were obtained non-invasively using DermTech’s (La Jolla, CA) adhesive patch sample collection platform to enable gene expression and mutation analyses. The same lesions were surgically biopsied immediately afterwards to establish histopathologic diagnoses for comparisons between PLA gene expression results, mutational analyses, and morphological assessment. The histopathologic diagnoses were established by three dermatopathologists who agreed on the diagnoses of non-melanoma excluding SDN (n=50, nevi with no, mild, or moderate atypia as well as non-melanocytic lesions) or melanoma (n=30). Twenty-three of the lesions analyzed were cases deemed SDN

by at least one dermatopathologist reader. PLA positivity was defined by presence of detectable RNA transcripts encoding LINC and/or PRAME. Mutation positivity was defined as the presence of BRAF, NRAS, and / or TERT promoter mutations by Sanger sequencing in DNA from skin lesion tissue obtained via adhesive patches. We excluded BRAF V600E mutations seen in common nevi. Statistical significance of PLA gene expression differences for the groups depicted in Figure 1 was calculated using Fisher's Exact test.

## RESULTS

PLA gene expression test results of 103 pigmented skin lesions clinically suspicious for melanoma and sampled non-invasively via adhesive patches, melanoma hotspot driver mutation analyses from the same non-invasively obtained samples, and histopathologic diagnoses enabled by surgical biopsies of the same lesions immediately after adhesive patch sampling are summarized in Table 1.

We compared SDN (n=23) with thin invasive (median tumor thickness of 0.58mm) and in situ melanomas (n=30) as well as non-melanomas excluding SDN (n=50, 38 nevi and 12 non-melanocytic pigmented lesions including 8 solar lentigines, 2 seborrheic keratoses, and 2 squamous cell carcinomas). Detectable levels of LINC, PRAME or both target genes were found in 93% of melanomas, 61% of SDN, and 34% of non-melanomas excluding SDN (Figure 1). The addition of TERT mutation analyses to PLA gene expression increases the test's sensitivity for melanoma to 97% in this study. PLA-positive lesions histopathologically diagnosed as melanomas harbored TERT

mutations in 70% of cases while both SDN and non-melanoma lesions including nevi without severe histologic atypia harbored TERT mutations in 4% of cases. Analyses of BRAF non-V600E and NRAS mutations did not further enhance the test's sensitivity since the presence of these mutations overlapped with the presence of TERT mutations in the melanoma cases studied (Table 1). Most TERT-mutated cases were double positive for LINC and PRAME detection irrespective of the histopathologic diagnosis rendered (2/3, 1/1 and 18/21 in non-melanomas excluding SDN, SDN and melanomas, respectively). Only one lesion (a melanoma in situ) harbored a TERT mutation in the absence of LINC or PRAME expression.

## DISCUSSION

The aim of pigmented lesion examination is to identify melanoma at its earliest stages, when the highest cure rates are possible. We reported a 69% PLA specificity in our initial validation work that viewed the samples analyzed in the 2 broad categories of melanoma and non-melanoma diagnoses.<sup>3,11</sup> We now show SDN are almost twice as often positive by PLA and five times more often PLA double-positive than non-melanoma lesions excluding SDN also clinically suspicious of melanoma. Our data furthermore demonstrate that PLA combined with mutational analysis for TERT driver mutations improves test sensitivity to 97% for melanoma.

Overlapping histopathologic diagnostic criteria between early melanoma and dysplastic nevi has prompted concern that some SDN may actually represent evolving melanomas and some argue that they

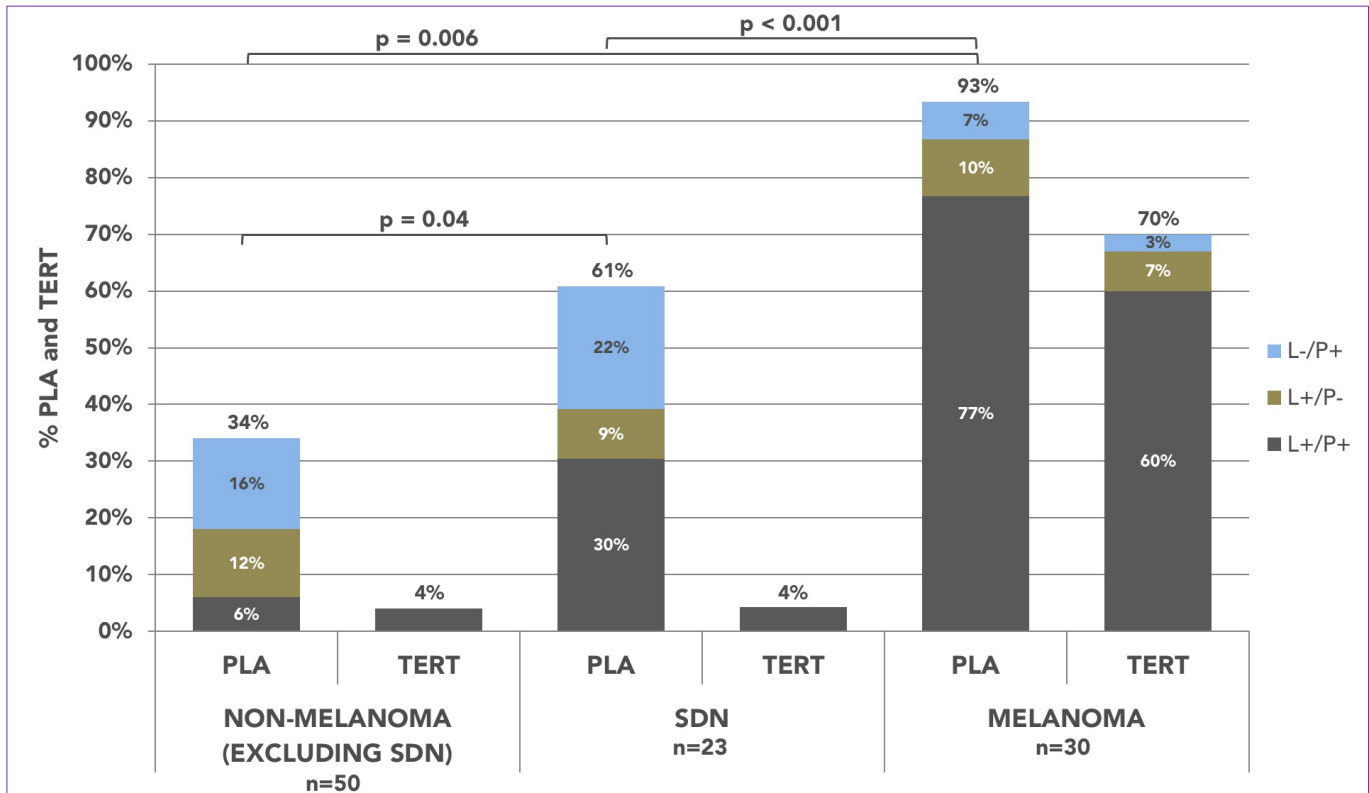
**Table 1.** Dermatopathology diagnoses, PLA gene expression test results and melanoma hotspot driver mutations in 103 pigmented skin lesions clinically suspicious of melanoma.

Dermatopathology Diagnoses of Lesions Clinically Suspicious for Melanoma	Total n = 103	LINC/ PRAME	N	Any + Mutation	>1 + Mutation	TERT +	NRAS +	BRAF + (non V600E)
	Malignant Melanoma (n = 24)	+/+		21	18	6	17	2
+/-			1	1	1	1	0	0
-/+			1	1	0	1	0	0
-/-			1	0	0	0	0	0
Melanoma in Situ (n = 6)	+/+		2	1	0	1	0	0
	+/-		2	1	0	1	0	0
	-/+		1	0	0	0	0	0
	-/-		1	1	0	1	0	1
Severely Dysplastic Nevi (SDN) (n = 23)	+/+		7	1	0	1	0	0
	+/-		2	0	0	0	0	0
	-/+		5	0	0	0	0	0
	-/-		9	0	0	0	0	0
Nevi with No, Mild or Moderate Dysplasia (n = 38)	+/+		3	2	0	2	0	0
	+/-		5	1	0	0	0	1
	-/+		8	0	0	0	0	0
	-/-		22	2	0	1	0	1
Non- Melanocytic Lesions (n = 12)	+/+		0	0	0	0	0	0
	+/-		1	0	0	0	0	0
	-/+		0	0	0	0	1	0
	-/-		11	2	0	2	1	0

should be treated as melanoma in situ.<sup>3,11-13</sup> Correlation between increased mutational burden of pigmented lesions and more aggressive histologic stage has been reported.<sup>1,10</sup> TERT promoter mutations are furthermore independently associated with poor overall survival and more aggressive disease.<sup>2,10,14</sup> The PLA utilizes gene expression to objectively identify higher risk lesions; TERT mutation analyses further expand actionable information. We show that TERT mutations are present in 70% of PLA positive melanomas, but in only 4% of SDN and non-melanoma lesions excluding SDN.

The PLA test enhanced by TERT mutation analyses identifies molecular changes in pigmented lesions and provides additional data to assess disease risk beyond what can be ascertained visually. The improved ability to stratify risk non-invasively can guide decisions about which lesions require aggressive versus conservative management, ultimately sparing patients unnecessary biopsies and excisions. Further, while biopsied dysplastic nevi can only be followed by monitoring for and judging the degree of atypia in re-pigmented scars, the non-invasive PLA leaves a lesion intact and permits use of more validated

**Figure 1.** PLA gene expression and TERT mutations in pigmented skin lesions clinically suspicious of melanoma. Detectable levels of LINC, PRAME or both target genes were found in 61% of SDN and in 93% of histopathologically melanomas. Melanomas harbored TERT promoter mutations in 70% of PLA positive cases while SDN and non-melanomas without SDN harbored TERT mutations in 4% of cases. LINC (L), PRAME (P), detected (+), not detected (-).



criteria of short-term monitoring. Real-world PLA use on now over 50,000 cases provides non-invasively obtained data sets that leave lesions intact for further monitoring and assessment of changes they may undergo.

A recent large US registry study of 3,418 cases confirmed that clinicians follow the guidance of the PLA (biopsying PLA positive lesions while clinically monitoring PLA negative ones) in over 98%, while reducing avoidable surgical biopsies of lesions clinically suspicious for melanoma by over 90%.<sup>15</sup> Findings presented here may further enhance clinician confidence in PLA use by further stratifying risk in pigmented lesions. TERT mutation analyses additionally help

differentiate SDN from early melanomas and further increase PLA performance.

Limitations of this study include the relatively small sample size and use of archival material. The generalizability of our findings is limited by the fact that in clinical practice most lesions are evaluated by a single pathologist or dermatopathologist with significant variability in diagnosing borderline lesions.<sup>3</sup>

## CONCLUSION

PLA positivity increases with histologic atypia of pigmented skin lesions. Combining TERT mutation analyses with melanoma-associated

March 2020 Volume 4 Issue 2

gene expression provides additional genetic information to further non-invasively risk-stratify pigmented lesions. These findings furthermore support that pigmented lesions exist on a spectrum of genomic atypia that may prove useful in identifying borderline lesions beyond their morphological appearance.

**Conflict of Interest Disclosures:** SRJC has done consulting for DermTech, LKF is an investigator for and an advisor of DermTech, BJ and ZY are employees of DermTech

**Funding:** This study was partially supported by DermTech

### Corresponding Author:

Laura K. Ferris  
University of Pittsburgh Medical Center (UPMC)  
Department of Dermatology  
Falk Medical Building, Suite 5A  
3601 Fifth Avenue  
Pittsburgh, PA 15213  
Phone: 412-647-4200  
Email: [ferrlk@upmc.edu](mailto:ferrlk@upmc.edu)

### References:

1. Shain AH, Yeh I, Kovalyshyn I *et al.* The Genetic Evolution of Melanoma from Precursor Lesions. *N Engl J Med* 2015; 373(20):1926-1936.
2. Ferris LK, Gerami P, Skelsey MK *et al.* Real-world performance and utility of a noninvasive gene expression assay to evaluate melanoma risk in pigmented lesions. *Melanoma Res* 2018; 28(5):478-482.
3. Elmore JG, Barnhill RL, Elder DE *et al.* Pathologists' diagnosis of invasive melanoma and melanocytic proliferations: observer accuracy and reproducibility study. *BMJ* 2017; 357:j2813.
4. Kim CC, Swetter SM, Curiel-Lewandrowski C *et al.* Addressing the knowledge gap in clinical recommendations for management and complete excision of clinically atypical nevi/dysplastic nevi: Pigmented Lesion Subcommittee consensus statement. *JAMA Dermatol* 2015; 151(2):212-218.
5. Duffy K, Grossman D. The dysplastic nevus: from historical perspective to management in the modern era: part I. Historical, histologic, and clinical aspects. *J Am Acad Dermatol* 2012; 67(1):1 e1-16; quiz 17-18.
6. Engeln K, Peters K, Ho J *et al.* Dysplastic nevi with severe atypia: Long-term outcomes in patients with and without re-excision. *J Am Acad Dermatol* 2017; 76(2):244-249.
7. Gerami P, Yao Z, Polsky D *et al.* Development and validation of a noninvasive 2-gene molecular assay for cutaneous melanoma. *J Am Acad Dermatol* 2017; 76(1):114-120 e112.
8. Ferris LK, Jansen B, Ho J *et al.* Utility of a Noninvasive 2-Gene Molecular Assay for Cutaneous Melanoma and Effect on the Decision to Biopsy. *JAMA Dermatol* 2017; 153(7):675-680.
9. Haqq C, Nosrati M, Sudilovsky D *et al.* The gene expression signatures of melanoma progression. *Proc Natl Acad Sci U S A* 2005; 102(17):6092-6097.
10. Ferris LK, Moy RL, Gerami P *et al.* Noninvasive Analysis of High-Risk Driver Mutations and Gene Expression Profiles in Primary Cutaneous Melanoma. *J Invest Dermatol* 2019; 139(5):1127-1134.
11. Duncan LM, Berwick M, Bruijn JA *et al.* Histopathologic recognition and grading of dysplastic melanocytic nevi: an interobserver agreement study. *J Invest Dermatol* 1993; 100(3):318S-321S.
12. Diagnosis and treatment of early melanoma. NIH Consensus Development Conference. January 27-29, 1992. *Consens Statement* 1992; 10(1):1-25.
13. Culppepper KS, Granter SR, McKee PH. My approach to atypical melanocytic lesions. *J Clin Pathol* 2004; 57(11):1121-1131.
14. Nagore E, Heidenreich B, Requena C *et al.* TERT promoter mutations associate with fast-growing melanoma. *Pigment Cell Melanoma Res* 2016; 29(2):236-238.
15. Brouha B, Ferris LK, Skelsey MK *et al.* Real-world utility of a non-invasive gene expression test to rule out primary cutaneous melanoma: a large US registry study. *JDD* 2020; 19(3); doi:10.36849/JDD.2020.4766.